

Efficacy of Intralesional Alcohol Injection as Preoperative Treatment of Upper Lip Arteriovenous Malformation

Prasetyanugraheni Kreshanti, Gentur Sudjatmiko, Nur Anindhawati
Jakarta, Indonesia.

Background: Management of vascular malformation remains a major challenge because treatment carries a substantial risk of morbidity and recurrence of the fundamental problem. Intra-lesional 96% alcohol injection as a combination with other treatment modalities has good-to-excellent results.

Methods: Six-year old female with a 5-year history of arteriovenous malformation on her upper lip underwent intralesional alcohol injection under general anesthesia. Afterward we performed excision of the lesion. During the surgery we used Satinsky intestinal clamp to control the bleeding by compressing the artery

Result: The follow up period was 9 months; there were no complications and no signs of relapse. Aesthetically, the result perceived as acceptable to the parents and other viewers.

Conclusion: In cases of arteriovenous malformation involving the lip the technique of injecting alcohol 96% intralesional in conjunct with reducing blood loss by using Satinsky intestinal clamps had an acceptable result aesthetically.

Keywords: lip, vascular malformation, sclerotherapy, absolute ethanol, Satinsky intestinal clamp

Latar Belakang: Penatalaksanaan malformasi vaskular merupakan permasalahan pelik karena adanya resiko morbiditas dan rekurensi. Injeksi intralesi alkohol 96% dikombinasikan dengan modalitas terapi lainnya akan memberikan hasil yang baik

Metodologi: Anak wanita usia enam tahun dengan riwayat malformasi arteriovenous pada bibir atas menjalani injeksi alkohol intralesi dalam bius umum. Setelahnya kami melakukan eksisi lesi. Intraoperasi kami menggunakan klem usus Satinsky untuk mengontrol perdarahan dengan menekan arteri.

Hasil: Pasien dilakukan follow up selama 9 bulan dan tidak tampak adanya komplikasi dan kekambuhan. Secara estetik didapatkan hasil yang dapat diterima orangtua pasien dan penilai lainnya.

Ringkasan: Kasus malformasi vaskular yang melibatkan bibir atas dapat ditatalaksana menggunakan injeksi alkohol intralesi dengan kombinasi menggunakan klem usus untuk mengurangi perdarahan.

Kata Kunci: lip, vascular malformation, sclerotherapy, absolute ethanol, Satinsky intestinal clamp

Arteriovenous malformation (AVM) is not a static malformation; it progresses over time and recurs after treatment. AVM may also cause disfigurement, destruction of tissues, and obstruction of vital structures. Although the presence of an AVM may be troublesome, it is the expansion of the lesion that is the primary cause of morbidity. AVM worsens over time¹.

Hemangiomas were differentiated from vascular malformations by their clinical appearance, histopathological features, and biological behavior^{2,3}.

The traditional treatment for AVM in the head and neck is surgical excision if possible. Excision and reconstruction of a large, diffuse AVM should be done with caution because (1) cure is rare and the recurrence rate is high; resulting deformity is often worse than the appearance of the malformation and (3)

From the Division of Plastic Surgery, Department Of Surgery, Cipto Mangunkusumo General National Hospital, Universitas Indonesia. Presented in The Fifteenth Annual Scientific Meeting of Indonesian Association of Plastic Surgeon. Semarang, Central Java. Indonesia.

Disclosure: The authors have no financial interest to disclose or any commercial implication regarding to this study.



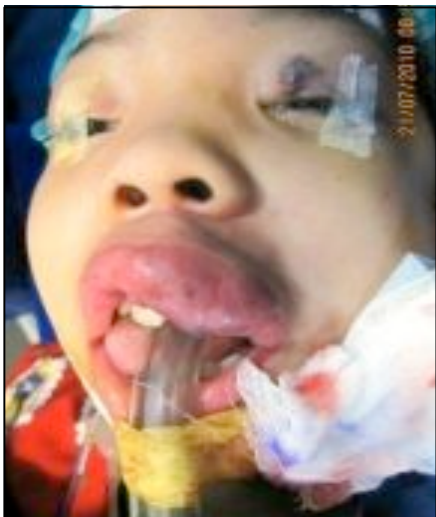(3) resection is associated with significant blood loss, iatrogenic injury, and morbidity⁴.

First-line surgical resection is not indicated owing to large amount of blood loss, incomplete resection with risk of recurrence and usually poor cosmetic results. Intralesional alcohol injection is one of the treatment options available. When injected preoperatively, it also helps to reduce surgical blood loss and to delineate the surgical extent of resection⁵.

Another important issue of the management of AVM in our country is cost issue. In Indonesia congenital deformities are not covered by most of insurance, while intralesional alcohol injection may need several procedures before surgery which will surely cost a lot.

Case 1

A 6-year-old female presented with a 5 year history of a compressible pulsatile reddish lesion on her upper lip (Figure 1). There was no history of any preceding trauma. The lesion was warm, not easy to bleed, with no tenderness. Initially the lesion was small with diameter of less than 1cm. As the child grew, the lesion grew as well. We performed biopsy on the lesion and the result was consistent with AVM.



Figures 1. Before injection. Large mass at the upper lip resulting in distortion of the facial anatomical structure without functional impairment.

We performed percutaneous intralesional sclerotherapy using alcohol 96% under general anesthesia. The volume injected was 0.5-1.5 ml per one treatment session. The sclerotherapy was repeated 2 times with 1-2 month intervals. A clinical improvement in the overall size, discoloration of the lesion and also the density was achieved. (Figure 2).

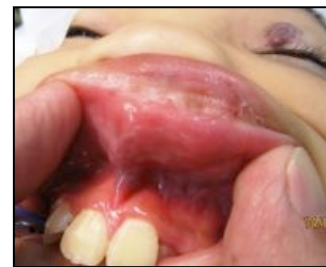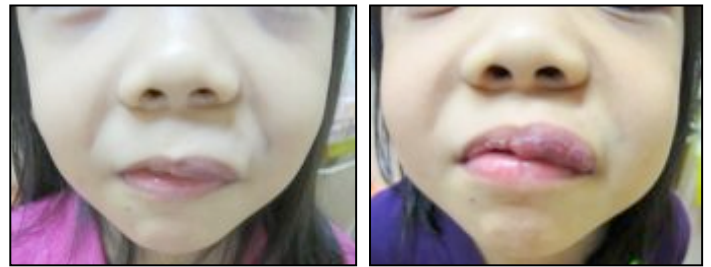


Figure 2. (upper left) 1 month after 1st alcohol injection; (upper right) 1 month after 2nd injection. The size was already decreased; (bottom) 2 months after 2nd injection, a clinical improvement was achieved.

Afterward we performed excision of the lesion with compression on the left and right labial artery using Satinsky intestinal clamps during the surgery to control bleeding. The defect was closed with a mucosal flap preserving the orbicularis oris muscle. Tie-over dressing was applied to obtain compression effect to control bleeding after the intestinal clamps were removed.

Four days after surgery, there are no sign of complications, the lip looks symmetrical, but skin marks from intestinal clamp persisted. Eight days after surgery, the clamp marks disappeared completely (Figure 3). After 9 months of follow-up, there are no signs of complications or recurrence.

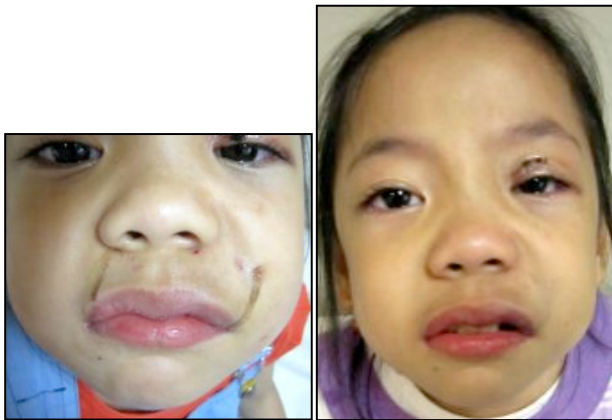

Figure 3. (left) Skin marks from intestinal clamp still exist; (right) Eight days after surgery, the clamp marks disappeared completely, the symmetrical already appear

DISCUSSION

Depending on their size and location, AVM may cause pain and anatomic distortion and may even threaten life. They can affect not only the skin, but also muscles, nerves, joint spaces, and even bones. AVM on specific region such as face can cause disfigurement. Especially in a young child not psychologically prepared for a major procedure^{1,6}.

Vascular anomalies were first treated by surgeons. Complete excision of an AVM nidus proved very difficult and very hazardous in that massive hemorrhage often occurred. Partial resections could cause an initial good clinical response but with time the patient's symptoms usually recurred or worsened. Over time, it became apparent to vascular surgeons that, as stated by D.E. Szilagyi, M.D., "with few exceptions, their cure by surgical means is impossible^{7,8}.

The traditional treatment for AVM in the head and neck is surgical excision. In some difficult lesions where they permeate and envelop normal structures, such as the facial nerve, a less-invasive treatment is required to preserve these structures. Intralesional alcohol injection is one of the treatment options available. When injected preoperatively, it also helps to reduce surgical blood loss and to delineate the surgical extent of resection⁵.

Several injections would be needed to achieve desired result. *Prasetyono* et al found 2.63 sessions of sclerotherapy were required. In this case, we performed 2 sessions of sclerotherapy. The sclerotherapy was performed under general anesthesia because of the pain during injection and the need of careful monitoring^{1,8}.

In this patient, we used 96% alcohol as sclerosing agent because its low cost, antiseptic quality, wide availability, and ease of use. It is the most effective sclerosant available and it is known to have the lowest recurrent rate. The downside is it requires general anesthesia because it is very painful¹.

After 2 times of injection, the patient refused to have another injection. She was traumatized of being injected and did not want to wait any longer for the result. That is why after 2 injections we performed surgery to remove the lesion^{5,7}.

During surgery, *Satinsky* intestinal clamps were used to compress the left and right labialis artery. This procedure is to artificially decrease the blood flow so the risk of the surgery would be decreased or even avoided. The clamp marks on the skin disappeared completely after 8 days.

Other aspect to be considered in this case is finance. Since AVM is a congenital deformity, initially the insurance refused to cover any procedures performed on this patient. While in this patient, we had planned several procedures which would cost a lot. Fortunately, finally the insurance was willing to cover the cost.

CONCLUSION

After 9 months of follow-up (picture will be taken in May 2011), there were no complications and no signs of relapse, and aesthetically the result perceived as acceptable to the parents and other viewers. The choice to use sclerotherapy in combination with surgery gives acceptable and stable result. Besides, by having sclerotherapy before surgery, the lesion became more solid with more distinct margin and smaller in size. Thus, it is technically easier to perform excision and also helped to reduce surgical blood loss.



Other modality we used to reduce blood loss is by using Satinsky intestinal clamps. Even though there were skin marks of the clamps, but they were completely disappeared in 8 days after surgery. Thus, it is advisable to use Satinsky intestinal clamps to reduce surgical blood loss.

Gentur Sudjatmiko, M.D.

Plastic Surgery Division

Cipto Mangunkusumo General National Hospital

Jalan Diponegoro.No.71, Gedung A, Lantai 4.

dr_gentur@yahoo.co.id

Acknowledgements

We gratefully thank B.J.Bismedi, MD for his assistance in reviewing and Nandita Melati Putri, M.D. for basic editing and proof-reading of the article.

REFERENCES

1. Greene AK, Orbach DB. Management of Arteriovenous Malformations. *Clin Plastic Surg* 2011; 38: 95–106.
2. Sudjatmiko G. *Petunjuk Praktis Ilmu Bedah Plastik Rekonstruksi*. Jakarta: Yayasan Khasanah Kebajikan; 2007.P. 54-58.
3. Kesuma DA, Atmodiwirjo P. Hemangioma on Bilateral Cleft Lip: Case Report. Paper presented at : 13th Annual Scientific Meeting of Indonesian Association of Plastic Surgeons ; June 4, 2009; Batu, Indonesia
4. Lee CH, Chen SG. Direct Percutaneous Ethanol Instillation For Treatment of Venous Malformation in the Face and Neck. *Br J Plast Surg* 2005; 58: 1073–8.
5. Prasetyono TOH, Kreshanti P. Efficacy of Intralesional Alcohol Injection as Alternative and/or Complementary Treatment of Vascular Malformations – a Systematic Review. *Journal of Plastic and Reconstructive Surgery* 2010; 63: 1071–9.
6. Hammer FD, Boon LM, Mathurin P, et al. Ethanol Sclerotherapy of Venous Malformations: Evaluation of Systemic Ethanol Contamination. *J Vasc Interv Radiol* 2001; 12 :595–600.
7. Saito N, Sasaki S, Furukawa H, et al. Percutaneous Sclerotherapy for Arteriovenous Malformations of the Face in the Outpatient Clinic. *Acta Otorhinolaryngologica Italica* 2010;30:149-152
8. Szilagyi DE, Smith RF, Elliott JD, Hagegerman JH. Congenital Arteriovenous Anomalies of the Limbs. *Arch Surg* 1976; 111:423-429.