

The Simplest Modified Vacuum Assisted Closure to Treat Chronic Wound : Serial Case Report

Danu Mahandaru, Rosadi Seswandhana
Yogyakarta, Indonesia.

Background: Among the current adjunctive treatment modalities available for the treatment of chronic wounds, vacuum-assisted closure therapy showed promising results. However, the VAC Therapy system is expensive, requires extensive amounts of product and needs a power source at all times. In this article, the authors introduce and review their experience with simplest modified vacuum assisted closure (smVAC) for treatment of chronic wound.

Methods: Three patients with chronic wound came to the plastic surgery division at Sardjito hospital in early 2010 and were treated using simplest modified vacuum assisted closure (smVAC). After the wound bed was ready, split thickness skin graft (STSG) were performed to close the wound and smVAC was used to assist the graft placement.

Results: All patients underwent successful healing and reported satisfaction with their results. There were no side effects from using this device, such as maceration, necrosis and bleeding.

Summary: Through the serial cases, the smVAC had shown to serve its function in providing adequate vacuum pressure for wounds. It is an alternative to the original vacuum assisted closure.

Keywords: *chronic wound, vacuum assisted closure, split thickness skin graft, simplest modified vacuum assisted closure*

Latar Belakang: Diantara berbagai cara pengobatan tambahan yang tersedia untuk penanganan luka kronis, terapi vacuum-assisted closure (VAC) menunjukkan hasil yang menjanjikan. Namun sistem terapi VAC ini mahal, membutuhkan produk dengan jumlah yang banyak serta sumber daya setiap kali penggunaannya. Pada artikel ini, penulis memperkenalkan dan menguraikan pengalaman pengobatan luka kronis dengan simplest modified vacuum assisted closure (smVAC).

Metode: Tiga pasien dengan luka kronis datang ke Divisi Bedah Plastik Rumah Sakit dr. Sardjito pada awal tahun 2010, dilakukan perawatan dengan menggunakan simplest modified vacuum assisted closure (smVAC). Setelah siap, luka ditutup menggunakan split thickness skin graft (STSG) dan smVAC membantu proses penempelan graft.

Hasil: Semua pasien mengalami proses penyembuhan luka dengan baik dan dilaporkan puas terhadap hasilnya. Tidak terdapat efek samping seperti maserasi, nekrosis, maupun perdarahan akibat alat yang digunakan.

Kesimpulan: Berdasarkan kasus serial ini, smVAC mampu menyediakan tekanan vakum yang adekuat pada luka. Alat ini dapat digunakan sebagai alternatif apabila tidak dapat menggunakan alat yang orisinal.

Kata Kunci: *chronic wound, vacuum assisted closure, split thickness skin graft, simplest modified vacuum assisted closure*

Chronic wound poses an ongoing challenge for its management. It is a major source of morbidity, lead to considerable disability, and is associated with increased mortality. Therefore, it has a significant impact on public health and the expenditure of health care resources^{1,2}. Among

the current adjunctive treatment modalities available for the treatment of chronic wounds, vacuum-assisted closure therapy has shown promising results. It is a new technique of management of wound based on the principle of application of controlled negative pressure^{3,4,5}. It is frequently recommended for use with chronic wounds, acute and traumatic wounds,

From Division of Plastic Surgery, Department Of Surgery, dr. Sardjito Hospital, Universitas Indonesia. Presented in The 14th Annual Scientific Meeting of Indonesian Association of Plastic Surgeon, Balikpapan, East Kalimantan, Indonesia

Disclosure: *Neither of the authors has any financial interests, sources of funds, commercial affiliations, or associations related to the publication of this article.*

flaps, grafts, and other non-sutured wounds such as dehisced incisions. The mechanism of this procedure is to reduce exudates and colonization of bacteria, stimulate angiogenesis, increase perfusion, and stimulate granulation tissue^{6,7,8}.

However, the VAC Therapy system has its disadvantages. It is expensive and requires extensive amounts of product and machinery, as well as functioning suction, and a power source at all times. In addition, the VAC Therapy system requires a trained and vigilant nursing staff^{1,3}. To overcome those problems, the idea to invent a modification of VAC system with simple, accessible, save, massively produced and cheap materials took place. The modification aimed to reach the same benefits as the original one. In some countries the VAC systems modification were conducted by using accessible materials in each country as well using the device for different kinds of wound^{4,9}. For example:

- Italia, 2001: Mobile-VAC for the treatment of lower limb ulcers.
- England, 2001: Inexpensive-VAC, employing a conventional disposable closed-suction drainage system.
- Atlanta, 2001: Negative pressure dressings (by continuous wall suction) in treatment of hidradenitis suppurativa

- Japan, 2003: Topical negative pressure using a drainage pouch without foam dressing for the treatment of undermined pressure ulcers.
- Indonesia, 2005: A simple modified-VAC system for improving skin graft survival, treat chronic wound, etc.

METHODS

MODIFICATION OF VACUUM ASSISTED CLOSURE

The reference for modification was the experience on modified vacuum assisted closure in Jakarta 2005. Simplification of the device was conducted by changing the manometer indicator with the infused balloon. In vitro test was done using 20 Otsuka blood transfusion set (elastic ball type) as shown in Figure 1.

From the test above, the smVAC cannot quantify in exact the strength of vacuum pressure applied (with an estimated range between 110-390 mmHg). The negative pressure recommended for chronic ulcer is 125 mmHg. The pressure indicator used for this device was if one balloon was deformed the estimated pressure was \pm 110 mmHg. A model

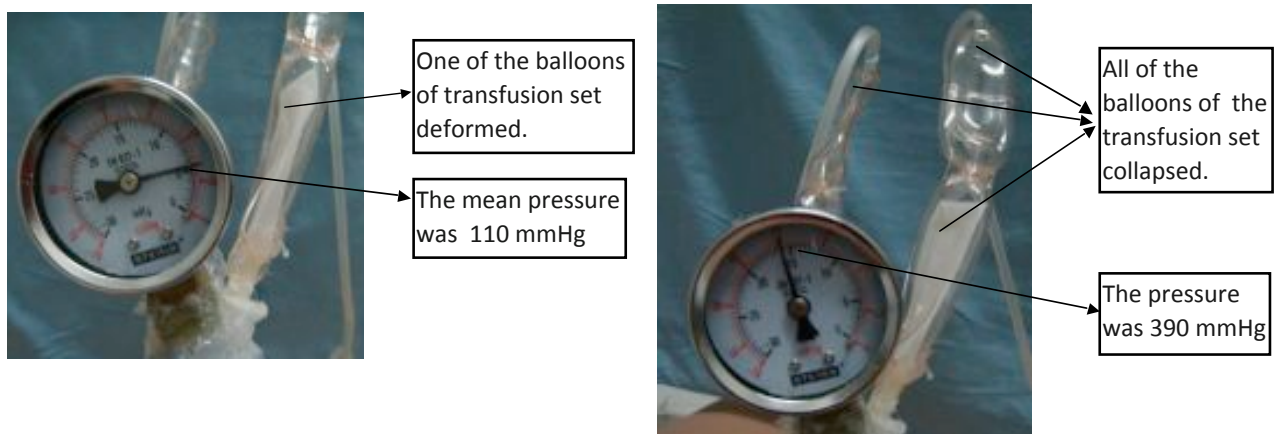


Figure 1. (Left) The pressure when one of the balloon of transfusion set deformed (110mmHg); (Right) The pressure when all of the balloons of transfusion set collapsed (390mmHg)

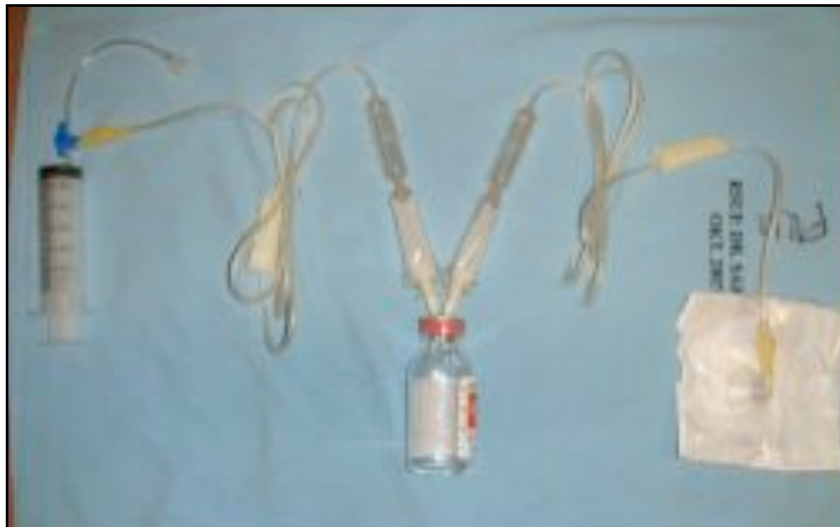

Figure 2. The simplest vacuum assisted closure (smVAC)

Table 1. Specification of smVAC

Specification	Alternative
Negative Pressure Supply Unit	Disposable Syringe 50 ml with three way infusion set
Disposable unit	100 cc closed rubber-sealed vacuum bottle
Canister	Sterile gauge
Dressing	Grass tulle
Tubing	Transparent Adhesive-Occlusive Dressing (tegaderm®, opsite®)
	Connector
	Otsuka blood transfusion set (elastic ball type)

of the device is shown in Figure 2 and the specification listed in Table 1.

CASE 1

The first case was a male, 52 years old with a history of 25 years chronic wound at the lateral side of the right ankle region. The wound had bad granulation tissue and necrotic tissue. First the wound was debrided, then smVAC was applied at the wound. After 7 days, the smVAC was released, and the wound had resulting good granulation tissue. Split thickness skin graft used to cover the wound and the smVAC was used to assist graft placement. Fifth day later, the smVAC was released and the STSG adhere completely to the wound bed. On the tenth day, the graft had successfully covered the wound. (Figure 3)

CASE 2

The second case was a male, 24 years old with chronic wound at the posterior side of the left ankle region. The wound was exudative, with inadequate granulation tissue and exposed

sutures at the Achilles tendon. Debridement and refreshment of the wound by marginal excision were done. Afterwards, the smVAC was applied to the wound. At the twelfth day, the smVAC was released and the wound already had good granulation tissue and ready to be covered with skin graft. Split thickness skin graft was used with the smVAC to assist graft placement. Seventh day after STSG, vacuum was released and the graft took 100% in process. Finally, at the 13th day after STSG, the graft successfully covered the wound. (Figure 4)

CASE 3

The third case is 28 years old male, with 4 months multiple chronic wound at the left lower leg region. There were two wounds that had necrotic tissue and boundary with unhealthy skin. First the patient underwent debridement and refreshment of the wound edges. Then the smVAC was applied at the wound. At the fifth day, the vacuum was released and the wound revealed good

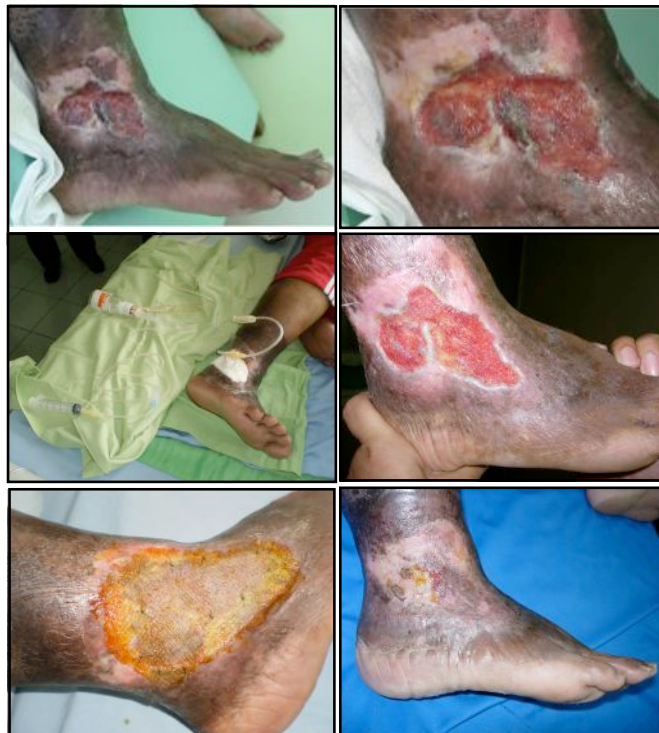

Figure 3. (Upper left) Male 52 year old with 25 years chronic wound at lateral side of the right ankle region, (Upper right) The wound has bad granulation and necrotic tissue, (Middle left) application of simplest modified vacuum-assisted closure(smVAC), (Middle right) 7 days after smVAC (the wound is ready to be closed), (Lower left) 5 days after STSG + smVAC, (Lower right) 10 days after STSG + smVAC

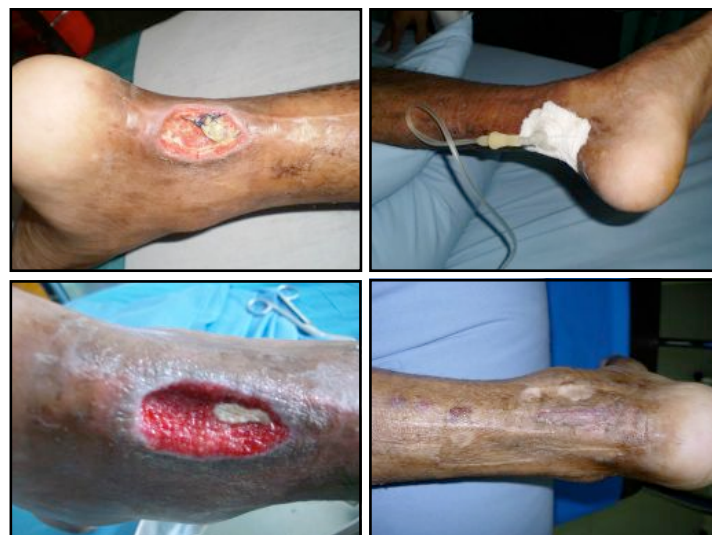

Figure 4. (Upper left) Male 24 year old with 4 months chronic wound at posterior side of the left ankle region, the wound is wet and there were sutures at Achilles tendon, (Upper right) application of smVAC, (Lower left) 12 days after smVAC (the wound is ready to close), (Lower right) 13 days after STSG + smVAC

granulation tissue and ready to be covered by graft. Then split thickness skin graft were performed and smVAC used again to assist the

graft placement. Ten days after STSG the vacuum was released and the graft took 100% in process (Figure 5)

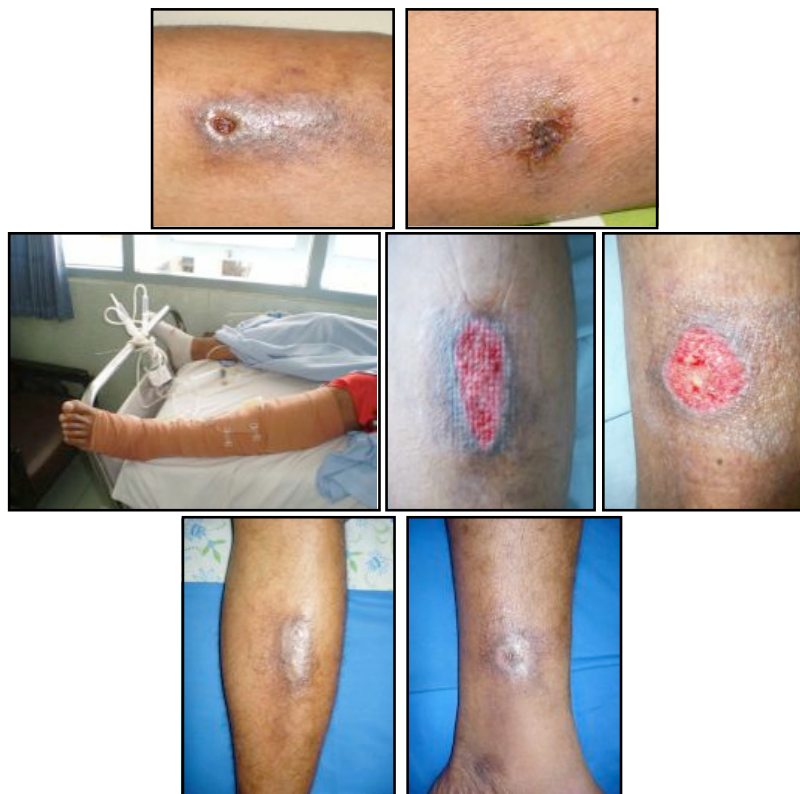

Figure 4. (Upper left and right) Male 28 year old with 4 months multiple chronic wound at the left lower leg region, There were two wounds that had necrotic tissue and surrounded by unhealthy skin, (Middle left) application of simplest modified vacuum-assisted closure (smVAC), (Middle right) 5 days after used the vacuum (the wound is ready to be closed), (Lower left and right) 4 weeks after treatment. the vacuum (the wound is ready to be closed), (Lower left and right) 4 weeks after treatment

RESULT

All patients underwent successful healing and reported satisfaction with their results. There were no side effects from using this device, such as maceration, necrosis or bleeding. Patient did not feel discomfort or pain in using this device. Patients' characteristics are shown on Table 2.

DISCUSSION

The use of a vacuum system (Vacuum-Assisted Closure, USA) to help wound healing was introduced in 1997 by Argenta et al. Negative pressure seems to promote drainage of excessive fluids from the wound bed and interstitial space, reducing bacterial population and edema, enhancing local blood flow and

Table 2. Characteristic of the patients, result and side effect of the treatment

Patient	Sex	Age	Diagnosis	Result	Time	Pain/ discomfort	Side Effect	Satisfy
1	Male	52 y.o	Chronic ulcer at right ankle region	Full healing	12 days	-	-	+
2	Male	24 y.o	Chronic ulcer at posterior side of ankle region (achilles)	Full healing	19 days	-	-	+
3	Male	28 y.o	Multiple chronic ulcer at left lower leg	Full healing	15 days	-	-	+

granulation tissue formation. Other effect of vacuum closure is to pull of the wound borders to the center, reducing the wound diameters due to retraction. Surgeons believe that the treatment of difficult wounds should be primarily surgical, and the VAC system was reported to accelerate the preparation of the wound to definitive surgical closure. In other words, it improves the local conditions in patients who are waiting a better clinical situation to be submitted to surgical procedures. The pressure is extremely important.

With these concepts in mind, we introduced in our service, the simplest modified vacuum assisted closure. The system was used to treat 3 cases of difficult wounds, thus preparing them to definitive surgical closure. The vacuum treatment aimed also to improve the take of skin grafts. We are conducting a clinical trial on this subject. However, as our first impression was quite positive, and we decided to report this initial experience.

SUMMARY

Through our serial cases, the smVAC cannot quantify in exact the strength of vacuum pressure applied (we can only estimate a range between 110-390 mmHg) but it has shown to serve its function in providing adequate vacuum pressure for wounds. The benefits of our modified VAC is that it is cheaper and can be constructed using simple clinical devices. This device can be used as an alternative device, if we could not use the original ones.

M. Rosadi Seswandhana

*Plastic Surgery Division, Department of Surgery,
Faculty of Medicine, Gadjah Mada University, Dr.
Sardjito General Hospital, Yogyakarta, Indonesia
rsandhana@gmail.com*

REFERENCES

1. Simon Higgins, The effectiveness of vacuum assisted closure (VAC) in wound healing. Centre for Clinical Effectiveness – Evidence Report (DRAFT), 2003.
2. Joseph E, Hamori CA, Bergman S, et al. A prospective, randomized trial of vacuum-assisted closure versus

- standard therapy of chronic non-healing wounds; Wounds. 2000;12(3)
3. Argenta LC, Morykwas MJ. Vacuum-assisted closure: a new method for wound control and treatment: clinical experience. *Ann Plast Surg.* 1997;38(6):563-576; discussion 577.
4. Moues, CM, van den, Bemd GJ, Heule, F, Hovius, SE. Comparing conventional gauze therapy to vacuum-assisted closure wound therapy: a prospective randomised trial. *J Plast Reconstr Aesthet Surg* 2007; 60:672.
5. Moues, CM, Vos, MC, van den, Bemd GJ, et al. Bacterial load in relation to vacuum-assisted closure wound therapy: a prospective randomized trial. *Wound Repair Regen* 2004; 12:11.
6. Mendez-Eastman, S. Guidelines for using negative pressure wound therapy. *Adv Skin Wound Care* 2001; 14:314.
7. Meredith Warner, MD; Chance Henderson, MD; Warren Kadrmaz, MD; Darius T. Mitchell, MD. Comparison of Vacuum-assisted Closure to the Antibiotic Bead Pouch for the Treatment of Blast Injury of the Extremity. *ORTHOPEDICS* 2010; 33:77
8. KCI,V.A.C.® TherapyClinicalGuidelines :A Reference Source for Clinicians, July 2007.
9. Melissa W. Kaufman, Douglas W. Pahl .Vacuum-assisted closure therapy: wound care and nursing implications. *Dermatology Nursing*, August, 2003